



PATIENT

Chewy McClintock

SPECIES

Canine

BREED

Shih Tzu

SEX

Male Neutered

AGE

10 years

WEIGHT

15.6lbs

PRESENTING CLINICAL SIGNS

History: Recheck echo. Progressive heart murmur, now grade 5/6. Recently started coughing with exertion. Lungs sound normal. No medications. BP: 140mmHg.
-CXR: Show left-sided cardiomegaly without CHF.
-Pertinent previous echo findings (3/2022 MML): CVD B1. LA: 1.7, LV: 3.0.

ELECTROCARDIOGRAPHIC FINDINGS

A six lead ECG is available at 50mm/s; 10mm/mV. The average heart rate is 1165bpm (range 140-188bpm). The rhythm is sinus in origin, with a p for every QRS complex and vice versa. The P wave morphology is positive with a normal dimension. Normal PR. The QRS morphology is positive with normal dimension. MEA is normal. Isolated APCs are noted; singles only. No VPCs, pauses or other dysrhythmias observed.

ECG diagnosis: Normal sinus rhythm with respiratory variation. Rare, isolated APCs.

ECHOCARDIOGRAM FINDINGS

2D, m-mode, color flow and doppler imaging is available. The mitral valve is diffusely thickened with prolapse into the left atrial lumen. There is severe eccentric mitral regurgitation present. The MR velocity is normal. There is severe left atrial enlargement. There is mild left ventricular dilation. Left ventricular systolic function is hyperdynamic. Normal right heart. Mild thickening of the tricuspid valve with mild TR. Normal velocity. There is normal systolic flow velocity across the aortic valve. The aortic valve appears trileaflet with normal mobility. The main pulmonary artery is normal in diameter. The pulmonic valve is normal in appearance. No pericardial/pleural effusion or cardiac masses are seen.

INTERPRETED BY

Maggie Machen Lamy,
DVM, DACVIM
(Cardiology)

IMAGING PERFORMED BY

Loetitia St-Jacques,
LVT/RVT

HOSPITAL NAME

Mount Rose Animal
Hospital

REFERRING VET

Dr. Weldon

INVOICE

28044

DATE

1/2/23

CARDIAC CHART

CANINE CARDIAC PARAMETERS	MR VMAX (m/s)	TR VMAX (m/s)	LA/AO (Boon method)	LA/AO (Heart Base; Swe)	FS (%)	EF (%)	EPSS (cm)
NORMAL PARAMETER	4.5-5.5	<2.7	1.3	<1.6	28-40	40-100	<0.6
PATIENT	5.6	2.2	NM	2.0	42	74	NM
CANINE CARDIAC PARAMETERS	HR (BPM)	AV VMAX (m/s)	PV MAX (m/s)	BODY WEIGHT (kg)	LA 2D short axis Base view (cm)	LVIDd Avg; 2D and m-mode short axis (cm)	LVIDs Avg; 2D and m-mode short axis (cm)
NORMAL PARAMETER	50-100	0.7-1.7	0.7-1.6	BELOW	BELOW	BELOW	BELOW
PATIENT	150	1.2	0.9	7.1	2.8	4.0	2.3
*Normal chamber parameters expressed as a mean value (SD)				3	1.27 (5.3)	2.46 (2.46)	1.36 (5.5)
BODY WEIGHT DEPENDENT PARAMETERS				5	1.40 (4.5)	2.74 (5.2)	1.60 (4.7)
<i>*Note: All measurements based upon multi-modal images and methods. An average value is reported.</i>				10	1.50 (3.8)	3.27 (3.5)	2.06 (3.1)
				15	1.83 (2.0)	3.71 (2.4)	2.43 (2.1)
				20	2.02 (1.9)	4.14 (2.2)	2.80 (2.0)
				25	2.18 (2.4)	4.48 (2.9)	3.10 (2.5)
				30	2.33 (3.3)	4.83 (3.9)	3.39 (3.4)
				35	2.48 (4.3)	5.17 (5.0)	3.69 (4.5)
				40	2.62 (5.2)	5.48 (6.1)	3.96 (5.4)
				50	2.88 (7.1)	6.07 (8.3)	4.46 (7.4)

Adapted from June Boon, Veterinary Echocardiography, 1998
Rishniw M and Hollis NE, J Vet Intern Med 2000; 14:429-435
Hansson et al, Vet Rad and Ultrasound 2002
Bonagura et al. Echocardiography: principles of interpretation, Vet Clin North Am 15:1177, 1995



PATIENT

Chewy McClintock

SPECIES

Canine

BREED

Shih Tzu

SEX

Male Neutered

AGE

10 years

WEIGHT

15.6lbs

INTERPRETED BY

Maggie Machen Lamy,
DVM, DACVIM
(Cardiology)

IMAGING PERFORMED BY

Loetitia St-Jacques,
LVT/RVT

HOSPITAL NAME

Mount Rose Animal
Hospital

REFERRING VET

Dr. Weldon

INVOICE

28044

DATE

1/2/23

INTERPRETATION OF THE FINDINGS & FURTHER RECOMMENDATIONS

Chronic degenerative valve disease persists with severe mitral and mild tricuspid regurgitation. Compared to the prior study, there is certainly evidence of progression from mild to severe disease which is surprising given the timeframe. The LA is significantly dilated indicating a high risk for clinical signs going forward. No additional concurrent issues are documented.

A cough in this patient with severe heart disease is likely multi-factorial in origin, including mainstem bronchi compression and/or potentially some degree of upper or lower airway disease. Early CHF/pulmonary edema should also be considered; however, this is less likely based upon the reported history. Baseline CXR are recommended. Regardless, recommend institute cardiac supportive medications including a weak diuretic (spironolactone) and advise close monitoring at home for need for Lasix therapy. Pending response, cough suppression (up to q4-6 hours) may also be helpful for mechanical cough. Monitoring of sleeping breathing rates is recommended as the best way to screen for CHF at home.

The ECG is largely normal, although two isolated APCs are identified. These are likely secondary to stress and atrial dilation in this patient. No treatment is warranted and simple follow up is advised.

Omega fatty acid supplementation and mild salt restriction may also be of some long-term benefit. Monitor for development of a worsening cough, labored breathing, exercise intolerance or collapse episodes. Long term prognosis is guarded to poor, with an average survival time of 8-9mo for canine patients with active pulmonary edema on medications, however they generally are able to maintain a good quality of life for that period. Patient will always be at risk for recurrent CHF, development of arrhythmias/LA tear, syncope and/or sudden death in the future.

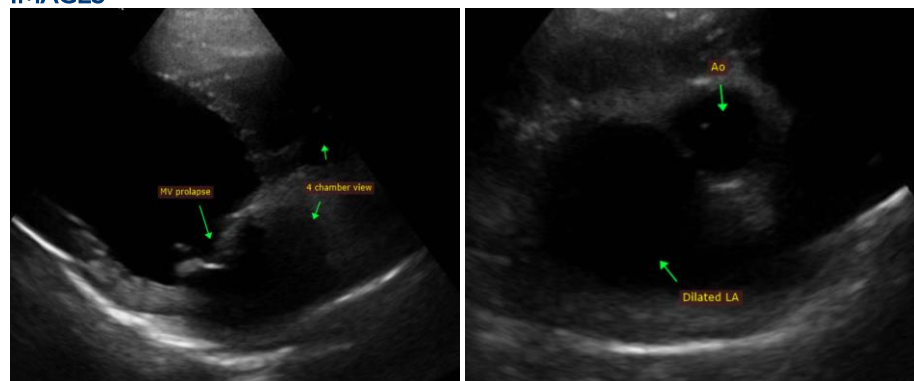
PLAN

Institute Pimobendan 0.3mg/kg PO q12h. Institute Spironolactone 1-2mg/kg PO q12h. Baseline BP recommended. If >130mmHg, institute ACE-I (benazepril or enalapril) 0.5mg/kg PO q12h. Consider hydrocodone with homatropine for QOL (0.2-0.4mg/kg PO up to q4-6 hours PRN for cough; available in 5/1.5mg tabs and 5mg/5ml liquid suspension).

A renal panel is recommended in 1-2 weeks, then every 3-4 months lifelong.

A recheck echocardiogram and ECG are recommended in 6 months to screen for progression, sooner if clinical signs arise.

IMAGES





PATIENT

Chewy McClintock

SPECIES

Canine

BREED

Shih Tzu

SEX

Male Neutered

AGE

10 years

WEIGHT

15.6lbs

INTERPRETED BY

Maggie Machen Lamy,
DVM, DACVIM
(Cardiology)

**IMAGING
PERFORMED BY**

Loetitia St-Jacques,
LVT/RVT

HOSPITAL NAME

Mount Rose Animal
Hospital

REFERRING VET

Dr. Weldon

INVOICE

28044

DATE

1/2/23

The information and recommendations provided are based on the images presented by the referring veterinarian. No evaluation can be communicated regarding pathology that was not visible in the image/video clips provided.

Thank you for this referral. This report was generated using transcription software, and minor dictation errors may be present. If the clinical or image interpretation does not parallel your findings or if I can be of any further assistance, please contact me.

Maggie Machen Lamy, DVM
Diplomate of the American College of Veterinary Internal Medicine (Cardiology)
info@sonopath.com